

# PILOT STUDY FOR THE CHARACTERIZATION OF A MURINE MODEL OF HYPERPLASTIC GROWTH IN COLON

Bote-Chacón J\*, Moreno-Lobato B\*, Sánchez-Margallo FM\*

\*Jesús Usón Minimally Invasive Surgery Center.Cáceres

## INTRODUCTION:

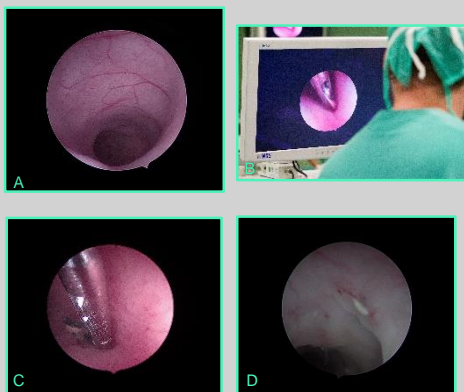
The PICCOLO project proposes a new compact, hybrid and multimodal photonics endoscope based on Optical Coherence Tomography (OCT) and Multi-Photon Tomography (MPT) combined with novel red-flag fluorescence technology for in vivo diagnosis and clinical decision support. For its development it includes different phases of validation. Within this framework, the present study has as main objective: **To characterize a model of rat colonic hyperplasia, which will be used for the development and validation of the previously mentioned endoscopic technology.** Secondary objectives: **Procure the reproducibility of the model chosen and determine the optimal time, after induction of the model.**

## MATERIAL AND METHODS:

12 animals (*Rattus norvegicus*), Wistar, Males and Females <1 year old, randomly distributed.

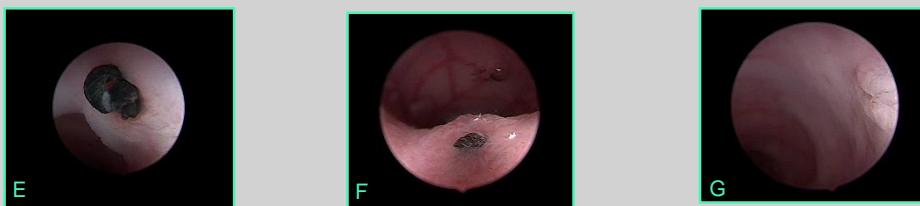
Group 1 (n = 2): By laparotomy, a non-resorbable suture (Silk 4/0), not stenosing, is placed through the wall of the colon. Group 2 (n = 2): By endoscopy, a 0.3 mm long segment of a polymeric catheter is inserted, which is fixed to the wall of the colon by means of a suture. Group 3 (n = 2): By means of endoscopy, a self-expanding and uncoated metallic stent is placed in the colon. Group 4 (n = 2): A superficial laser resection of the colonic mucosa is performed by endoscopy. Group 5 (n=4): As an extension of the most optimal model.

Weekly, the animals were anesthetized again to perform a colonoscopy, which determined the degree of mucosal growth in descending colon and colonic biopsies were extracted weekly (4 weeks).



## RESULTS:

Group 1. Growth around the sutures after the second follow-up, diagnosed as hyperplastic polyps after a histopathological analysis. Group 2: The catheter disappeared. Group 3: Stent caused mechanical intestinal obstruction. Group 4: The injuries caused by the laser were resolved weekly. Group 5: The model chosen was Group 1, In all of them we found growths after the second follow-up (We are waiting for the histopathology results for these animals).



A) Image of healthy tissue, descending colon. B) Procedure of extraction of biopsies in the colon. C) Biopsy removal near suture. D) Hyperplastic growth Group 1 E) Hyperplastic growth Group 5. F) Hyperplastic growth Group 5. G) Hyperplastic growth Group 5.

## CONCLUSION:

We have obtained a surgical model of colonic hyperplasia that solves limitations of other traditional models that only produce hypertrophy.

This proposed model allows its reproducibility for subsequent studies.

## REFERENCES

- Bartoli R, Boix J, Odena G. Colonoscopy in rats: An endoscopic, histological, and tomographic study. *World J Gastrointest Endosc.* 2013 May 16;5(5):226-30.
- Berho M, Wexner SD, Botero-Anug AM, et al. Histopathologic advantages of compression ring anastomosis healing as compared with stapled anastomosis in a porcine model: a blinded comparative study. *Dis Colon Rectum.* 2014;57:506-13.
- Caruso A, Conigliaro R, Manta R, et al. Fully covered self-expanding metal stents for refractory anastomotic colorectal strictures. *Surg Endosc* 2015;29:1175-8.
- Pommergaard HC, Rosenberg J, Schumacher-Petersen C, et al. Choosing the best animal species to mimic clinical colon anastomotic leakage in humans: a qualitative systematic review. *Eur Surg Res* 2011;47:173-81.
- Rackoff AI, Brady PG. Foreign body reaction mimicking submucosal tumor of the colon. *Clin Gastroenterol Hepatol.* 2008 Oct;6(10):A30.
- Treuting, P. M., Dintzis, S. M., & Montine, K. S. (n.d.). Comparative anatomy and histology: a mouse, rat, and human atlas.

Fondo Europeo de Desarrollo Regional  
Una manera de hacer Europa

GR18199



JUNTA DE EXTREMADURA  
Consejo de Gobierno de Extremadura



Centro de Investigación en Medicina Experimental  
de Cáceres



PHOTONICS<sup>21</sup>  
PROYECTO ESPECIAL PARA EL BACHILLERATO

